

Letter to the Editor

Vesicle Formation in Early Oral Submucous Fibrosis: Insights and Implications

 **Rahul Anand**,¹  **Gargi Sarode**,¹  **Namrata Sengupta**,¹  **Deepak Pandiar**,³  **Sachin Sarode**^{1,2}

¹Department of Oral Pathology and Microbiology, Dr DY Patil Dental College and Hospital, Dr DY Patil Vidyapeeth, Pune, Maharashtra, India
²Dr DY Patil Unitech Society's, Dr DY Patil Institute of Pharmaceutical Sciences and Research, Pimpri, Pune, Maharashtra, India
³Department of Oral Pathology and Microbiology, Saveetha Dental College and Hospitals, Saveetha Institute of Medical and Technical Sciences, Saveetha University, Chennai, India

Cite This Article: Anand R, Sarode G, Sengupta N, Pandiar D, Sarode S. Vesicle Formation in Early Oral Submucous Fibrosis: Insights and Implications. *EJMO* 2024;8(1):110–112.

Oral submucous fibrosis (OSF) is a chronic oral disorder characterized by the progressive fibrosis of the submucosa. OSF leads to an array of symptoms, including reduced mouth opening, burning mouth, mucosal rigidity, and exhibits potential malignant transformation.^[1] OSF is considered a chronic, progressive, and potentially malignant disorder affecting the oral mucosa, particularly the buccal mucosa, palate, and tongue. It is primarily characterized by fibrosis or the excessive deposition of collagen fibres in the submucosal connective tissue.^[2] It is strongly associated with the habitual chewing of areca/ betel nut, which contain bioactive compounds such as arecoline, arecaidine etc.^[3] Vesicle formation is not a typical feature of OSF however, occasional scenarios have been reported in the literature.^[4] Also, the pathogenesis of vesicle formation in OSF is not primarily associated with the clinical presentation of the disease.

The exploration of the potential pathogenesis underlying vesicle formation in the early stages of OSF constitutes a significant endeavour to unravel the intricacies of this multifaceted phenomenon. At its core, OSF represents a chronic oral disorder characterized by the progressive fibrosis of the submucosal connective tissues. However, indications from the literature suggest a subset of early OSF

cases presents with vesicle formation, which adds a novel layer to the understanding of its underlying mechanisms.^[5] This phenomenon, though less prevalent compared to the more established fibrotic manifestations, necessitates a thorough examination.

Initiation and Formation of Nucleation Sites

A plausible pathogenesis for vesicle formation in early OSF could be speculated based on the available literature and considerations. The path to vesicle development could potentially be initiated by the consumption of areca nut, a significant risk factor for OSF leading to formation of nucleation sites.^[3] Nucleation sites are tiny imperfections or surface irregularities in localized regions where a perturbation in the tissue integrity or cellular arrangement triggers an initial disturbance.

Habitual chewing exposes the oral mucosa to constituents of the areca nut, notably arecoline, which is believed to trigger an array of cellular responses. One pivotal aspect is the potential compromise of the epithelial barrier function due to arecoline-induced damage.^[6] This impairment could result in increased permeability, thereby allowing immune cells and inflammatory mediators to infiltrate the underlying

Address for correspondence: Rahul Anand, MD. Department of Oral Pathology and Microbiology, Dr DY Patil Dental College and Hospital, Dr DY Patil Vidyapeeth, Pune 411018, India

Phone: +919665058393 **E-mail:** rahul.anand303@gmail.com; rahul.anand@dpu.edu.in

Submitted Date: November 08, 2023 **Accepted Date:** December 22, 2023 **Available Online Date:** March 06, 2024

©Copyright 2024 by Eurasian Journal of Medicine and Oncology - Available online at www.ejmo.org

OPEN ACCESS This work is licensed under a Creative Commons Attribution-NonCommercial 4.0 International License.



ing oral mucosal tissues. Areca nut components have been reported to stimulate interleukin-1, interleukin-6, interleukin-8, cyclooxygenase-2, and tumour necrosis factor- in oral epithelial cells, and salivary levels of these cytokines correlate with the severity of OSMF.^[7, 8]

Fluid Accumulation and Surface Tension

Consequently, a localized inflammatory response may ensue, marked by the release of pro-inflammatory cytokines, chemokines, and recruitment of immune cells such as neutrophils and macrophages. These immune cells play an active role in addressing the perturbation, aiming to contain and resolve the insult.^[9] However, the inflammatory milieu facilitated by these cells could inadvertently contribute to the development of vesicles. The increased vascular permeability, a consequence of the ongoing immune response, may lead to fluid leakage into the interstitial spaces, culminating in the formation of vesicles beneath the damaged epithelium. The vesicular formations could, therefore, be interpreted as an adaptive response to the areca nut-induced insult.

Vesicle production is significantly influenced by surface tension, a basic feature of fluids caused by intermolecular interactions at the interface between the fluid and surrounding surfaces. The structural integrity of the mucosal layer is often maintained by elevated surface tension at the epithelial-submucosal junction. However, localised changes in surface tension brought on by cellular interactions, immunological mediators, or molecular rearrangements may weaken this interface and permit the accumulation of fluid below the mucosal layer.

Tissue Integrity, Pressure and Temperature

Increased vascular permeability and the flow of immune cells and inflammatory mediators to the afflicted location cause fluid buildup underneath the mucosal layer. The collection of fluid causes an increase in hydrostatic pressure inside the submucosal space. The submucosal layers, constrained by surrounding tissues and the epithelial layer, undergo deformation as they attempt to accommodate the increasing volume of accumulated fluid.

The mechanical stability of submucosal tissue is determined by its structural components, including collagen fibres, cellular junctions, and extracellular matrix. The mechanical stress put on these structural components when pressure develops owing to fluid buildup can cause mechanical deformation, causing the tissue to stretch and swell. This deformation can further enhance the formation of sub-epithelial vesicle in the context of reduced structural integrity.

Other physical attributes like temperature can also influence the initiation and progression of such submucosal vesicles by influencing the kinetics of cellular and molecular processes. Higher temperatures enhance cellular metabolism, immune cell activity, and inflammatory mediator release. These mechanisms can hasten fluid buildup and change the kinetics of tissue response. Furthermore, temperature-induced alterations in molecular interactions might affect surface tension, thereby leading to local epithelial-submucosal interface weakening.

Additionally, the autoimmune aspect which is increasingly recognized as a potential contributor to OSMF, could potentially intersect with vesicle formation.^[10] Chronic inflammation and tissue damage could stimulate the immune system to produce autoantibodies against oral mucosal antigens, thereby exacerbating vesicle formation. These autoantibodies may contribute to the blister-like structures by targeting components of the epithelium, leading to localized separation of cells and fluid accumulation. Eosinophilia in the submucosa of OSF patients has been reported in the literature.^[5]

Chronic inflammation and tissue damage stimulate fibroblast activation and collagen production. Early vesicles may undergo fibrotic changes due to ongoing inflammation and immune response. As fibrosis progresses, the vesicles' original appearance might be altered due to collagen deposition. The fibrotic changes could obscure the initial vesicular presentation, thereby masking the clinical presentation. A possible mechanism behind vesicle formation in OSF has been summarized in Figure 1.

However, it's crucial to acknowledge that this proposed pathogenesis is speculative in nature and requires further investigations and well-established evidence. The phenomenon of vesicle formation in early OSF warrants in-depth investigation through controlled studies, histopathological analyses, immu-

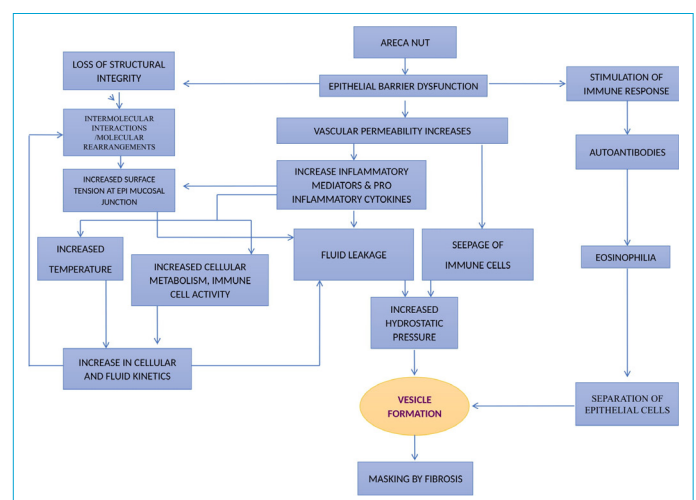


Figure 1. Plausible mechanism of vesicle formation in OSF.

nological profiling, and molecular studies. Comprehensive exploration of this intriguing manifestation could uncover new insights into the intricate mechanisms driving the initiation of OSF and its diverse clinical presentations.

The exploration of vesicle formation in early stages of OSF presents a promising avenue for understanding the disease's multifaceted pathogenesis. To elucidate this phenomenon, a series of comprehensive studies should be undertaken. Epidemiological investigations on a substantial scale would ascertain the prevalence and clinical characteristics of vesicle formation in early OSF cases along with histopathological analyses of mucosal biopsies which would provide insights into their histological attributes. Concurrently, immunological examinations could delve into the autoimmune aspect, profiling immune cells, cytokines, and autoantibodies within vesicle-associated tissues to unravel intricate immunopathogenic mechanisms. Future studies, *vis-à-vis* molecular investigations are also essential, focusing on the molecular pathways triggered by the areca nut constituents, particularly arecoline, to discern their role in initiating vesicle formation. Additionally, longitudinal studies tracking at-risk individuals over time would yield invaluable insights into the natural progression of vesicle-related events.

In the realm of therapeutic interventions and clinical considerations, early detection and monitoring strategies would be instrumental in identifying individuals in the initial stages of vesicle formation. Anti-inflammatory agents, both topical and systemic, could potentially mitigate the inflammatory response contributing to vesicle development. Exploring immune-modulating medications may address the autoimmune underpinnings, potentially influencing vesicle formation. Advanced techniques in tissue engineering could be harnessed to restore or regenerate compromised mucosal tissues, potentially preventing further vesicle occurrence. Equally important, patient education initiatives focusing on the dangers of areca nut chewing and behaviour modification are needed to raise awareness and influence cessation decisions. Rigorous clinical trials, employing placebo-controlled designs, would offer empirical evidence of the efficacy and safety of therapeutic interventions targeting early vesicle formation. A multi-disciplinary approach, involving oral health professionals, dermatologists, and immunologists, could foster comprehensive care for early OSF cases.

In conclusion, an in-depth investigation into the occurrence of vesicle formation in early stages of OSF holds tremendous promise for unravelling intricate aspects of the

disease's pathogenesis. By conducting rigorous studies encompassing epidemiology, histopathology, immunology, and molecular pathways, a comprehensive understanding of this phenomenon could be achieved. Furthermore, translating insights into potential therapeutic strategies and clinical considerations could usher in a new era of tailored management approaches for OSF patients.

Disclosures

Conflict of Interest: None declared.

Authorship Contributions: Concept – R.A., G.S.; Design – R.A., S.S., DP; Supervision – G.S., N.S., S.S.; Data Collection – R.A., G.S., S.S.; Literature search – R.A., G.S.; Writing – R.A., G.S., N.S.; Critical Review – D.P., S.S.

References

1. Pindborg JJ, Murti PR, Bhonsle RB, Gupta PC, Daftary DK, Mehta FS. Oral submucous fibrosis as a precancerous condition. *Scand J Dent Res* 1984;92:224–9.
2. Kerr AR, Warnakulasuriya S, Mighell AJ, Dietrich T, Nasser M, Rimal J, et al. A systematic review of medical interventions for oral submucous fibrosis and future research opportunities. *Oral Dis* 2011;17:42–57.
3. Prabhu RV, Prabhu V, Chatra L, Shenai P, Suvarna N, Dandekeri S. Areca nut and its role in oral submucous fibrosis. *J Clin Exp Dent* 2014;6:e569–75.
4. Pindborg JJ. Oral submucous fibrosis as a precancerous condition. *J Dent Res* 1966;45:546–53.
5. Pindborg JJ, Singh B. Formation of vesicles in oral submucous fibrosis. *Acta Pathol Microbiol Scand* 1964;62:562–6.
6. Gayathri K, Malathi N, Gayathri V, Adtani PN, Ranganathan K. Molecular pathways of oral submucous fibrosis and its progression to malignancy. *Arch Oral Biol* 2023;148:105644.
7. Babiuch K, Kuśnierz-Cabala B, Kęsek B, Okoń K, Darczuk D, Chomyszyn-Gajewska M. Evaluation of proinflammatory, NF-kappaB dependent cytokines: IL-1 α , IL-6, IL-8, and TNF- α in tissue specimens and saliva of patients with oral squamous cell carcinoma and oral potentially malignant disorders. *J Clin Med* 2020;9:867.
8. Chang MC, Chan CP, Chen YJ, Hsien HC, Chang YC, Yeung SY, et al. Areca nut components stimulate ADAM17, IL-1 α , PGE2 and 8-isoprostane production in oral keratinocyte: Role of reactive oxygen species, EGF and JAK signaling. *Oncotarget* 2016;7:16879–94.
9. Sodhi S, Sodhi JS, Khambete N, Kumar R, Marthala M, Sodhi NK. Expression of tumor necrosis factor α and its correlation with severity of oral submucous fibrosis: A case-control study. *Oral Surg Oral Med Oral Pathol Oral Radiol* 2014;117:704–8.
10. Sirsat SM, Khanolkar VR. Submucous fibrosis of the palate and pillars of the fauces. *Indian J Med Sci* 1962;16:189–97.